

Cartilage Regeneration on a Large Articular Surface Facilitated by Stress Shielding¹

Charles L. McDowell, M.D.², McGuire VA Medical Center,
Richmond, VA, **Jennifer S. Wayne, Ph.D.**, Virginia Commonwealth
University, Richmond, VA, **Robert Tuten, M.D.**, Virginia Common-
wealth University, Richmond VA, **Hunter H. McGuire Jr., M.D.**,
McGuire VA Medical Center, Richmond, VA

ABSTRACT

An animal model³ for the study of articular cartilage regeneration in-vivo facilitated by stress-shielding is introduced. The object of the model is to test the hypothesis that some form of cartilaginous tissue will grow upon a large joint surface in vivo with the joint in normal motion. The model utilizes the known capability of immature cells to differentiate. The source of cells is bleeding subchondral bone. In addition, the model provides a mechanically shielded environment in which cell differentiation and maturation can occur. The study showed that a substantial amount of tissue will grow in the animal model only when the new tissue is relieved of the normal joint stresses. The characteristics of the new tissue were observed after 12 weeks of growth. Gross observation showed that the new tissue grew to completely surround the shielding devices and covered the entire articular surface. The new tissue grew to the height of the shielded area (2 to 3mm.). Histologic evidence indicated the new growth was largely fibrous in nature but with some areas of newly differentiated chondrocytes. Biomechanical analyses quantified the tissue as being a soft, permeable neocartilage; biochemical evaluations demonstrated increased hydration with small amounts of proteoglycans. These characteristics are inferior to normal cartilage. Never the less, the tissue quality is as good or better than that obtained in other models and it grew to cover a significantly larger articulating surface than all other experimental models. Material obtained in this experiment provides a baseline of data for future experiments designed to manipulate the new tissue using tissue engineering methods and to learn how the new tissue will tolerate exposure to reintroduced normal stress.

Key terms: cartilage, in vivo, repair, interdisciplinary

INTRODUCTION

Multiple methods of producing new cartilage on subchondral bone surfaces are being studied. Our approach to placing new cartilagenous tissue on damaged or destroyed articular surfaces is based upon the following assumptions or hypotheses:

- 1 Source of Support: Veterans Affairs RR&D #AR-799C
- 2 Address correspondence to: Charles L. McDowell, M. D., McGuire Veterans Affairs Medical Center, Research Service 151, 1201 Broad Rock Boulevard, Richmond, Virginia 23249
- 3 U.S. Patent #5,108,441

1. That stem cells can differentiate and mature.
2. That the new growing tissue must be protected from mechanical stress during the early phase of maturation.
3. To be clinically relevant, we must learn how to cover large surface areas.
4. One is most likely to succeed if the joint is mobilized during the early stage of maturation because of the presumed nutritional advantage of motion and to prevent joint stiffness from occurring.

The most popular experimental method being studied presently is the application of biological resurfacing techniques (Coutts et al 1992; Green 1997; Hendrickson et al 1994; O'Driscoll et al 1986; von Schroeder et al 1991; Wakitani et al 1989). The hope for this approach is that one can apply a survivable living tissue on an articular surface in one step, and that it will maintain its homeostasis, i.e. respond/adapt to the stresses required through cellular control of its biochemical components. These methods have met with limited success in small defects.

Reparative techniques that employ grafting chondrogenic tissue (either as autografts or allografts) into small full-thickness defects have also been studied (Coutts et al 1992; Green 1997; Mow et al 1991; von Schroeder et al 1990; Wakitani et al 1994). The purpose of grafting these tissues into the defects is to introduce chondroprogenitor cells to produce neocartilage. Improvements in the quality of the neocartilage were found over other techniques, but predominantly in the short-term. Difficulties included lack of attachment of new tissue to surrounding normal cartilage and mechanical abrasion during articulation with a tendency for the new growth to shear away from the subchondral bone (Shapiro et al 1993). Transplanting chondrocytes in an appropriate matrix such as fibrin glue has also received attention (Hendrickson et al 1994). The quality of the neocartilage was superior to full-thickness circular defects left unfilled but still inferior to normal cartilage even at 8 months post-operatively.

Superficial shaving of areas of fibrillated or roughened cartilage has been the clinical treatment for a variety of joint surface problems, especially those that involve the patella. Most studies have found no evidence of repair tissue. Rather, the remaining layer of cartilage continues to deteriorate and pain and stiffness become worse. (Kim et al 1991; Mitchell and Shepard 1992).

Another clinical method which does appear to elicit a reparative response is abrasion arthroplasty (Altman et al 1992; Johnson 1986; Richmond et al 1985) or puncturing of the subchondral bone (Shands 1931; Mitchell and Shepard 1976; Rodrigo et al 1991). Perforating the subchondral bone surface to access the underlying blood supply is thought to begin the native response of clot formation and vascular invasion into the defect area as well as bring appropriate factors to aid in the repair. With a blood supply, neocartilage growth will occur up to the level of the cartilage surface or subchondral bone (stress shielded area) depending on the type of defect encountered (Shands 1931). There is no evidence showing that the new tissue will grow out of the small drill holes onto the joint surface. In addition, gross evaluation has suggested an improvement in the cartilage lesions of patients, but controlled in-vivo studies confirm that the repair tissue which does grow has poor histologic, biomechanical, and biochemical characteristics. Results from abrasion arthroplasty are unpredictable, especially in the long term (Kim et al 1991). These approaches and healing responses are demonstrated in Figure 1.

The outcome of all experimental and clinical work so far strongly suggests that articular cartilage possesses limited intrinsic ability for repair. (Gussenbauer 1871;

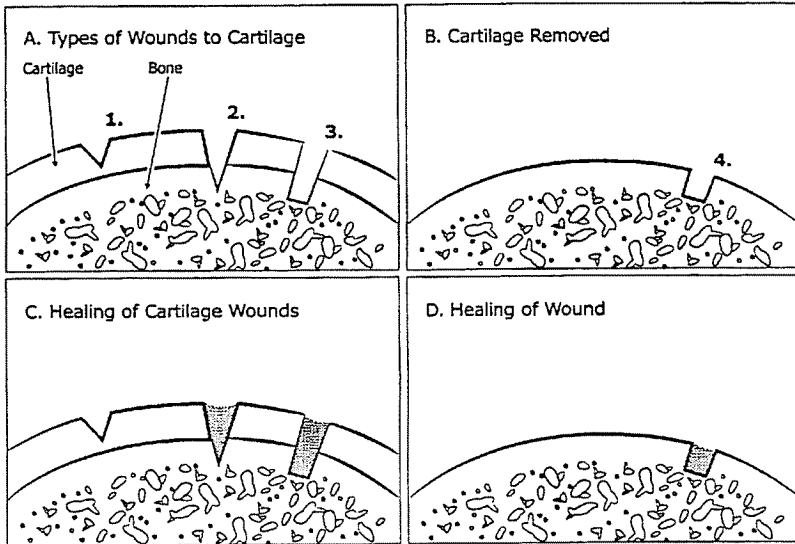


FIGURE 1: A) General classification of defects to articular cartilage - 1) partial thickness; 2) full thickness punctate; 3) full thickness blunt; B) denuded articular surface with perforation into subchondral bone; C) classic healing response of defects from (A); D) filling of perforated bone with neocartilage (B) only in defect.

Hunter 1743; Shands 1931) Currently, no method has proved satisfactory nor predictable for repairing damaged articular cartilage that encompasses a large portion of the joint surface and is durable in the long-term. Combining some of the features of previous reparative methods while avoiding difficulties encountered with others, this study investigates the intrinsic ability of joints to generate neocartilage over a large surface while minimally altering the joint environment.

For this study, it was assumed that neocartilage will grow and can be maintained on a large articular surface in an environment that shields the neocartilage from abrasive and compressive forces during the most fragile interval of regeneration while the joint moves through a full range of motion.

The in-vivo model was designed to facilitate neocartilage growth on a large articular surface where all the cartilage had been removed down to bleeding subchondral bone. The canine patello-femoral joint was used as the in-vivo model, and articular cartilage was removed down to raw bleeding subchondral bone from the patellar side of the joint. The patellar surface was protected from contact with the patellofemoral groove by insertion of dome-shaped polyethylene spacers which permitted articulation but separated the two articulating surfaces long enough for new tissue to grow on the denuded surface. The hypothesis of this study, that neocartilage can regenerate on a mechanically-shielded, subchondral bone surface after the cartilage has been removed to bleeding subchondral bone, is an extension of studies in the literature in which new cartilage was grown in small cylindrical or rectangular defects created in the articular cartilage (Shands 1931). Denuding an articular surface of all of the articular cartilage as in the model presented here has two benefits - it is more applicable clinically to generate a repair over a large portion of an articular surface versus the small cylindrical or rectangular defects as investigated in other studies. Second, other researchers have

noted a problem of lack of bonding between new cartilaginous tissue and adjacent normal cartilage (Mankin 1962). In this model, all of the new tissue grows from the subchondral bone surface; therefore, it is integral with and will not separate from the subchondral bone surface. Thus there is no bonding problem as all of the tissue is the same.

A multidisciplinary approach including gross, histological, biomechanical and biochemical assessments were made to evaluate the neocartilage grown in this model. Comparisons were made between neocartilage growth on patellae shielded from the normal stresses of joint motion and the control patellae which was exposed to normal mechanical stresses in the moving patellofemoral joint.

MATERIALS AND METHODS

Experimental Model

In this study, an in-vivo model was designed to test the hypothesis that neocartilage will grow on an articular surface where all the cartilage has been removed if bleeding subchondral bone has been exposed to access progenitor cells, and if the load-bearing articular surface is protected from normal mechanical stresses within the joint for a given amount of time.

The canine patello-femoral joint was used as the in-vivo model, and articular cartilage was removed from the patellar side of the joint. A device was designed to implant into this moving, load-bearing joint which would separate the two moving surfaces and allow new tissue to grow on the denuded patellar surface, but would not damage the contralateral articulating surface. The patellar surface was protected from contact with the patellofemoral groove by insertion of 1 joint spacer at each end of the patella. The dome shaped spacing devices are 3 mm high giving a protected area extending from the edges of the patellae up to a height of 3mm.

Twelve skeletally mature mongrel dogs, approximately 25kg, were used in this study. Management of the animals was governed by procedures approved by the Institutional Animal Care and Use Committee of Virginia Commonwealth University. The operative procedure on all animals involved bilateral surgery on the hindlimbs, making a medial parapatellar incision into the knee joint. The patellae were everted, and all of the articular cartilage and a thin layer of subchondral bone was removed with a high speed burr leaving a uniform surface of bleeding subchondral bone. Two 3.5mm holes were then drilled entirely through the cortices of the bone at the proximal and distal poles of one patella (experimental) and two small, dome-shaped polyethylene spacers inserted. Surface geometry of the spacers was determined from anatomical considerations of the canine patellofemoral joint. The spacers, with a threaded stem to hold them in position on the patellae, protruded into the joint for a distance of approximately 3 mm, giving a protected area on the experimental patella for the cartilage to grow on. The procedure was repeated on the contralateral knee (control), denuding the patella of articular cartilage as on the experimental side but holes were not made and spacers not inserted. Incisions were closed in standard fashion, and animals permitted ad libitum pen activity until the time of euthanasia at 6 or 12 weeks, with an equal number of animals assigned to each time period.

Gross visualization, histologic evaluation, and biomechanical and biochemical quantification were performed on the neocartilage from the patellae and the patel-

lofemoral grooves. The same evaluations were performed on patellae/grooves obtained from animals in other studies (that did not involve joint surgery) to serve as a normal baseline of cartilage characteristics. Assessing the grooves determined the extent, if any, of damage to this surface. The proximal 2/3 portion of the patellae was quantified biomechanically and biochemically while the remaining distal portion was evaluated histologically. Based on a recent study (Kwak et al 1993), the majority of the surface area of the patella is subjected to stresses at different angles of flexion. Thus, the sites of testing for biomechanical and biochemical analyses would constitute weight-bearing regions of the surface.

Gross and Histologic Analyses

Each patella and groove were quantitatively scored according to a grading scheme used in prior studies (Moran et al 1992; Pineda et al 1992), but modified to match specific characteristics of the current study (Table 1). Scoring was completed by two independent observers to insure consistency in the numbers assigned.

Specimens for morphological evaluation were processed using Haematoxylin and Eosin (H&E). The tissue was evaluated grossly for shape and contour and histologically for staining and uniformity of the cartilage. Cellular details included shape and distribution of the cells within the matrix. Each specimen of cartilage and the underlying bone was fixed in buffered formalin for 2-3 days, decalcified in a sodium citrate/formic acid mixture and processed for paraffin embedding. Serial sections were cut on a rotary microtome.

Sections were stained in haematoxylin for 2-5 minutes, washed well in running alkaline tap water until nuclei turned blue, counterstained with 1% aqueous eosin for one minute, dehydrated in alcohols, cleared in xylene and mounted in a synthetic resin medium. Nuclei appear blue to blue/black while the matrix is pink or light blue.

Biomechanical Quantification

The stress relief provided by the joint spacers was verified through the use of Fuji pressure sensitive film (Itochu International, New York). Preparation of patellae from normal canine knees obtained in other studies for insertion of spacers proceeded in a similar fashion as in the in-vivo surgical model. A simulated extension moment was applied to the knee, and the contact stress distribution of the joint at a given flexion angle imprinted onto the color-developing film. This process was done at three flexion angles - maximal extension, 45° of flexion and 90° of flexion.

The mechanical properties of the repair cartilage on each patella and groove was quantified by using material testing and current modeling theories in the biomechanics of cartilage. A biphasic nature of cartilage was assumed (Mow et al 1980) and applied to the experimental testing configuration of indentation (Mak et al 1987; Mow et al 1989). The properties determined were aggregate modulus (a measure of the stiffness of the tissue), apparent permeability (indicates the ease with which fluid flows within the tissue), and Poisson's ratio (indicative of tissue compressibility).

Specimens were tested in-situ (intact with underlying bone) by using a custom designed indentation apparatus (Figure 3). This device measured the instantaneous and time-dependent creep behavior of the cartilage under the application of a constant load. After equilibration for 15 minutes under a small preload, a weight was applied to the cartilage, and the instantaneous and creep deformation measured over a period

TABLE I. Objective grading criteria for analyzing cartilage in the repair model.

Patella Evaluation	Grade	Groove Evaluation	Grade
I. Extent of Coverage		I. Gross appearance	
> 75% surface area	4	Normal/no wear of cartilage	4
50-75% surface area	3	Slight wear/minimal loss of normal color	3
20-50% surface area	2	Moderate wear/visible areas of subchondral bone	2
< 25 % surface area		Significant wear/multiple denuded areas	1
No new cartilage	0	Severe wear/small areas of remaining cartilage	0
II. Cartilage color		II. Hypocellularity	
Normal	4	None	3
Yellow/slight loss of translucency	2	Slight	2
Brown/moderate loss of translucency	0	Moderate	1
III. Cartilage surface		Severe	0
Smooth	3	III. Chondrocyte clustering	
Irregular	2	None	2
Shallow clefts	1	< 25 % of cells	1
Clefts to tidemark	0	25-100% of cells	0
IV. Neocartilage thickness		IV. Surface integrity	
100% of normal	2	Normal	4
50-100% of normal	1	Surface irregularities	3
0-50% of normal	0	2% loss of cartilage thickness	2
V. Cell morphology		50% of cartilage thickness	1
Hyaline-like cartilage	4	Denuded cartilage to tidemark	0
Mostly hyaline-like cartilage	3		
Hyaline and fibrocartilage	2		
Fibrocartilage	1		
Nonchondrocytic cells	0		

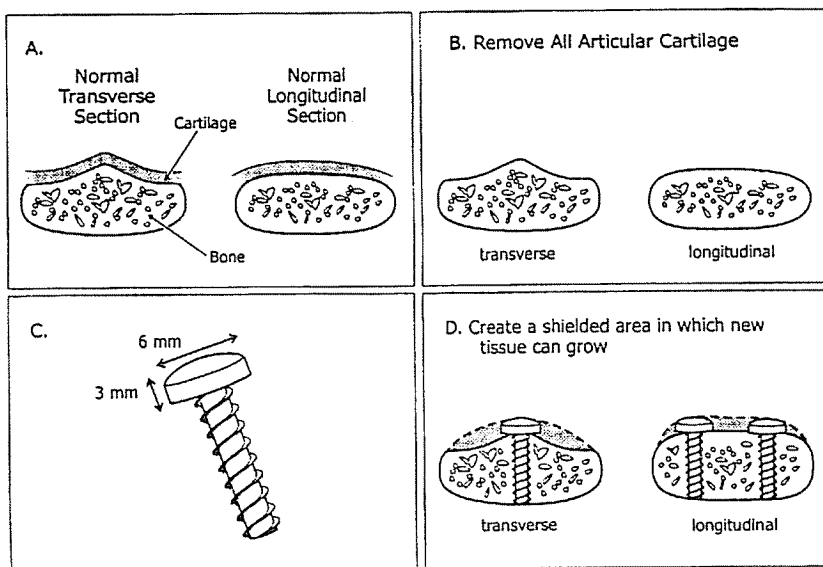


FIGURE 2. Schematic representation of: A) patella viewed in two planes showing cartilage layer on bone; B) All cartilage removed from subchondral bone C) joint spacer used to physically separate the patella from the patellofemoral groove; D) spacer placement on patella plus neocartilage growth.

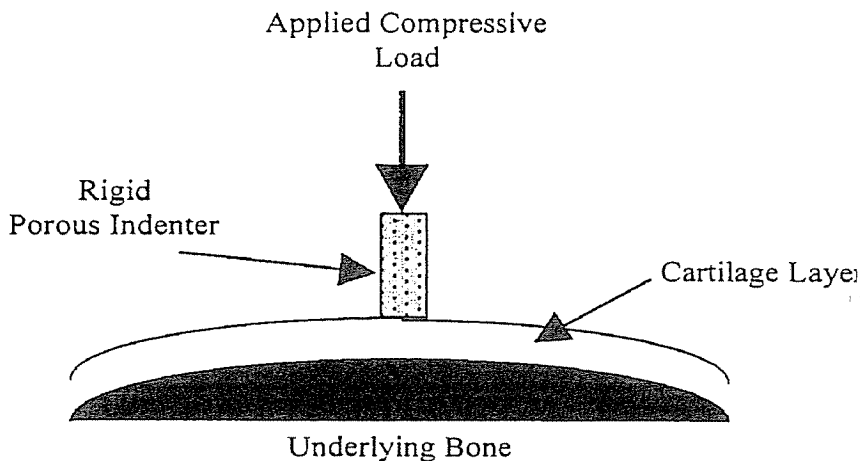


FIGURE 3. Schematic representation of the indentation experiment used for determining the biomechanical properties of the cartilage tested.

of 45 minutes or until equilibrium was reached. Equilibrium was set as a small value of the slope of the creep curve (10^{-06} mm/s). As a final parameter necessary for the analysis, the thickness of the cartilage was determined via a common optical technique (Jurvelin et al 1995). Each sectioned specimen was placed under a light microscope and the axis of indentation oriented parallel with vertical cross-hair in the reticle. The specimen was translated on a stage attached to a linear transducer as the horizontal cross-hair was aligned with the cartilage surface and then bone/cartilage interface to determine thickness of the tissue at the site of indentation.

Paired sets of data were collected from each indentation test - time of creep and surface compression - for use in property determination. A baseline of the biomechanical properties for normal patellar and patellofemoral groove cartilage were used as external normals, as described in Materials & Methods, to which experimental and control values were compared.

Determination of Cartilage Composition

Cartilage samples from the control and experimental patellae and patellofemoral grooves were analyzed to determine water, proteoglycan and collagen contents as described previously (Guilak et al 1994). To determine the water content, the samples were weighed before and after freeze-drying for 48 hours. The tissue was then digested with papain (1.25 mg/ 100 mg tissue) for 16 hours at 60°C, and aliquots of this digest were taken for separate analyses to determine hydroxyproline (as a measure of collagen) and sulfated glycosaminoglycan (S-GAG, a measure of proteoglycan).

To determine hydroxyproline content, the papain digest was hydrolyzed with HCl at 107°C overnight, dried, and then analyzed by a colorimetric procedure (Stegemann and Stadler 1967). The S-GAG content was determined by using the dye 1,9-dimethylmethylene blue (Farndale et al 1982), adjusted for use with a microtiter plate (Guilak et al 1994).

Statistical Analyses

The quality of the new growth on the patellae and any changes to the normal cartilage on the patellofemoral groove was statistically analyzed. One-way analyses of variance (ANOVA) were performed on the biomechanical and biochemical parameters calculated to determine the effect of the state of the repair (normal, 6, or 12 weeks).

RESULTS

Gross and Histologic Analyses

The gross photographs (Figure 4) and histologic photomicrographs (Figure 5) were typical of all specimens obtained from animals at the 6 and 12 week time periods. Gross evaluation of the control specimens (N=6 at each time point) showed no growth of new tissue on the cartilage denuded (control) articular surface where subchondral bone was in contact with the contralateral normal cartilage surface. At isolated sites where the denuded surface was not in contact, along the edges, there was a minimal growth of new tissue. However, in no specimen does the new growth rival the new growth on the experimental surface.

On the experimental knees (N=6 at each time point) (Figures 2, 4B and 4D), new tissue grew to completely surround the spacers on the entire patellar surface, and the thickness of the new tissue was equivalent to the height of the spacers (3mm).

Placement of the spacers on the patella is also evident in the photographs. The low power view shows new tissue growth silhouetting the site filled by the polyethylene spacer. The higher power is a view of the new tissue within the blocked out rectangle.

Grading of the gross and histologic appearance of the repair tissue was scored according to the scheme presented in Table I. At 6 weeks, a thick repair tissue covered at least 75% of the surface of the patellae. By 12 weeks, coverage increased to greater than 75%. The control patella where there was no mechanical stress shielding showed 50% or less coverage of the patella with tissue which varied in thickness from 0 where subchondral bone was exposed to a maximum of 50% of normal thickness in the 12 week specimens. Surface quality was graded as irregular. Shallow clefts were noted in the experimental tissue while clefts to the tide mark and exposed bone was evident in all of the control specimens.

The color of the new tissue on the experimental side was scored as brown/moderate loss of translucency at 6 weeks. The quality of the tissue improved by this measure to yellow/slight loss of translucency in the 12 week specimens. There was a tendency toward improved appearance in the control group as well. Cell morphology in the new tissue was characterized as fibrocartilage in all specimens, experimental and control.

The hyaline cartilage in the femoral groove was examined to evaluate the extent of damage that might have been produced by contact with the two polyethylene spacers. Table 2 suggests that injury occurred in that there was 50% loss of cartilage thickness and there was chondrocyte clustering and hypocellularity, changes presumed to result from injury. Abnormality of the hyaline cartilage in the femoral grooves in the 12 week specimens was graded worse in the control specimens at 6 weeks, but at 12 weeks the groove areas were graded worse in the experimental joints. This finding suggests that the spacers were well tolerated for 6 weeks and that significant damage to the normal hyaline cartilage occurs between 6 and 12 weeks.

Biomechanical Quantification

At all angles of flexion tested, the only contact made between the patella and the patello-femoral groove were at the sites of spacer placement. At maximal extension, the distal spacer was the point predominantly in contact with the groove while with increasing flexion, the point of contact moved proximally. This movement of the point of contact was the same trend found in a recent study by Kwak et al. (1993) using stereophotogrammetric methods. The stress relief was also confirmed visually as the separation between the two surfaces was clearly evident from both superior and lateral views.

The biomechanical analyses performed on the cartilage from the knees in this in-vivo model as well as on normal tissue from animals in other studies combined experimental testing, using the custom designed compression apparatus with analytical procedures to determine the biomechanical properties of the tissues. Indentation tests under a constant load were performed on the cartilage and the compressive deformation (creep) beneath the indenter was obtained. For the femoral grooves of both experimental and control knees as well as of normal cartilage, the site of testing was on the proximal third of the groove. For new growth on the experimental and normal patellae, the site of testing was chosen as the center of the patella (i.e. in between the two spacers on experimental patellae). Growth from control patellae could not be tested as the patellar surfaces were minimally covered as noted above.

TABLE 2. Gross and histologic grading of neocartilage from the patellae and corresponding patellofemoral grooves according to the scheme in Table 1. Values are presented as mean (standard deviation) with six animals at each time point.

	6 weeks		12 weeks	
	Experimental	Control	Experimental	Control
PATELLA EVALUATION				
I. Extent of coverage	3.00(1.15)	2.00(1.41)	3.43(0.79)	2.20(0.84)
II. Cartilage color	1.00(1.15)	1.00(1.15)	2.86(1.07)	1.60(0.89)
III. Cartilage surface	1.00(0.00)	0.20(0.45)	1.14(0.38)	0.20(0.45)
IV. Neocartilage thickness	2.00(0.00)	0.60(0.89)	1.57(0.53)	0.20(0.45)
V. Cell morphology	1.25(0.50)	1.20(0.45)	1.29(0.49)	1.00(0.00)
GROOVE EVALUATION				
I. Gross appearance	3.00(0.00)	2.50(0.58)	2.00(0.57)	2.60(0.89)
II. Hypocellularity	2.00(0.00)	2.25(0.96)	1.43(0.79)	1.80(1.10)
III. Chondrocyte clustering	1.00(0.82)	1.25(0.96)	0.14(0.38)	0.60(0.55)
IV. Surface integrity	2.75(0.50)	2.50(1.29)	1.14(0.69)	1.80(1.10)

Biomechanical results indicated that the new growth on the experimental patellae had a lower modulus and greater permeability than normal patellar hyaline cartilage (Figure 6). The modulus for cartilage from experimental patellae was significantly less than that for normal tissue ($p < 0.001$) but not different between 6 and 12 weeks. Thickness of the new growth was an average of 1.62 ± 0.51 mm at the site of indentation whereas the cartilage thickness from normal patellae was 0.67 ± 0.26 mm. The similarity to normal for the experimental grooves suggested that the grooves had not been damaged by contact with the spacers. Modulus values for grooves from the control side (in contact with a denuded patellar surface only) were 0.38 ± 0.17 MPa and 0.71 ± 0.30 MPa at 6 and 12 weeks respectively (mean \pm standard deviation). Variations were not significantly different from normal ($p < 0.18$). The moduli for repair tissue are comparable to that found in the short-term evaluations of other reparative studies (Mow et al 1991; von Schroeder et al 1990; Hale et al 1993; Woo et al 1987). The properties for normal cartilage were similar to other values (Athanasίου et al 1991).

Permeability of experimental patellar tissue, while having a greater mean than normal, was not significantly different from normal ($p > 0.13$). The Poisson's ratio for the experimental neocartilage was 0.02 ± 0.05 at 6 weeks and 0.04 ± 0.04 at 12 weeks (mean \pm standard deviation) while normal patellar cartilage is 0.03 ± 0.04 ($N=12$). The proximal third of the groove of these experimental knees, that in contact with the spacers, had a Poisson's ratio of 0.07 ± 0.08 at 6 weeks and 0.14 ± 0.16 at 12 weeks. Poisson's ratio for cartilage in the grooves from control specimens was 0.11 ± 0.14 at 6 weeks and 0.08 ± 0.11 at 12 weeks while normal values were 0.00 ± 0.01 . Statistical analyses between normal patellar cartilage and neocartilage exhibited similar findings for the Poisson's ratio as with the permeability.

Biochemical Quantification

For normal joints, the water content for articular cartilage varied from $63.9 \pm 10.0\%$ (mean \pm standard deviation, $N=3$) from the patellae to $69.9 \pm 4.7\%$ from the distal femoral grooves. In our surgical model, the amount of hydration increased on the experimental patellae: $80.6 \pm 3.1\%$ at 6 weeks ($N=6$) and $78.0 \pm 1.6\%$ at 12 weeks ($N=6$) ($p < 0.01$). Hydration in the grooves was within normal limits: experimental $76.4 \pm 4.3\%$ and $75.3 \pm 2.8\%$ at 6 and 12 weeks respectively ($p > 0.1$).

Proteoglycan content, expressed as micrograms of GAG (glycosaminoglycan) per microgram of dry tissue is shown in Figure 7a. Control grooves had values of 0.12 ± 0.04 and 0.14 ± 0.03 at 6 and 12 weeks respectively. The proteoglycan content in the femoral grooves was not affected by articulation with the spacers on experimental patellae ($p > 0.2$). The content on experimental patellar surfaces exhibited a trend towards a decreased content, which was not significantly different from normal ($p > 0.06$). Hydroxyproline content, representative of total collagen content, indicated an increase in patellae ($p < 0.02$) but not in grooves ($p > 0.1$) (Figure 7b).

DISCUSSION

This study confirms the hypothesis that, if a joint surface is completely denuded of hyaline cartilage down to a level of bleeding subchondral bone, new tissue will grow to completely cover the subchondral bone only if it is shielded from the mechanical effects of compression and shear by the opposing joint surface. Shielded environments to allow or foster growth of new fibrocartilaginous tissue have been created in other studies by drilling holes in subchondral bone (Shands 1931; Mankin 1962; Mankin 1982). In this "foxhole" type of environment, all mechanical stress is relieved and new tissue grows to fill the defect (Shands 1931; Shapiro et al 1993; Ito 1924; O'Driscoll and Salter 1986), but only up to the level of the surface. Other repair techniques that use chondrogenic tissue (either as autografts or allografts) into small full-thickness defects have also been studied (Coutts et al 1992; Green 1997; Mow et al 1991; Wakitani et al 1994). The purpose of grafting these tissues into the defects is to introduce chondroprogenitor cells to induce neocartilage growth. Improvements in the quality of the neocartilage were found over other techniques, but only for a short time. Difficulties with the methods have included lack of attachment of new tissue to surrounding normal cartilage (Mankin 1962) and mechanical abrasion during articulation with a tendency for the new growth to shear away from the subchondral bone (Shapiro et al 1993). Transplanting chondrocytes in an appropriate matrix such as fibrin glue has also received attention (Hendrickson et al 1994). The quality of the neocartilage was superior to full-thickness small circular defects left unfilled, but still inferior to normal cartilage even at 8 months post-operatively. We observe that new tissue will not grow onto the surface because of compression and shear stresses at the articulating surfaces as demonstrated in the above described techniques. Thus, the clinical relevance of these studies is limited to small defects only until a method of stress shielding for a yet to be discovered period of time can be devised. We believe this model is a step toward achieving that goal.

This project also provides important baseline data for future studies. Evaluation of the new tissue which grows in this model indicates that it was immature, having histologic, biomechanical, and biochemical characteristics different from normal hya-

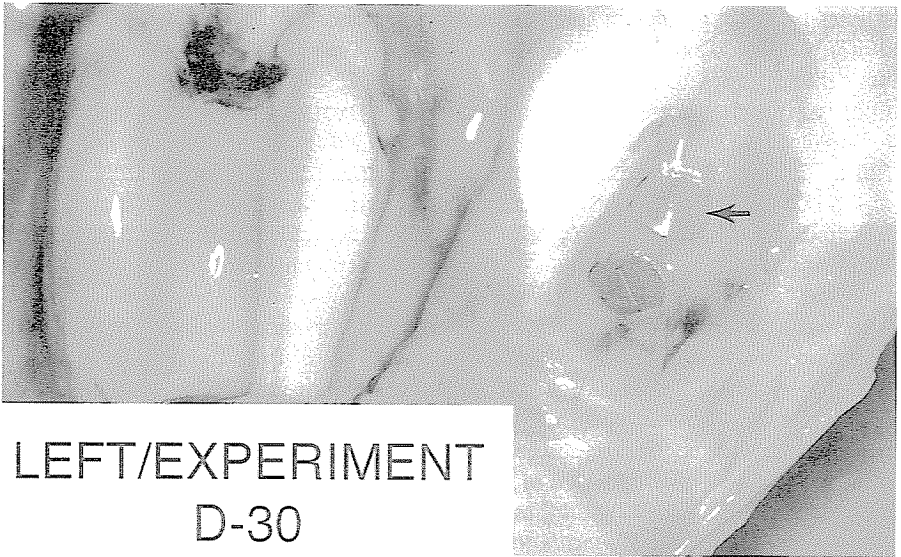
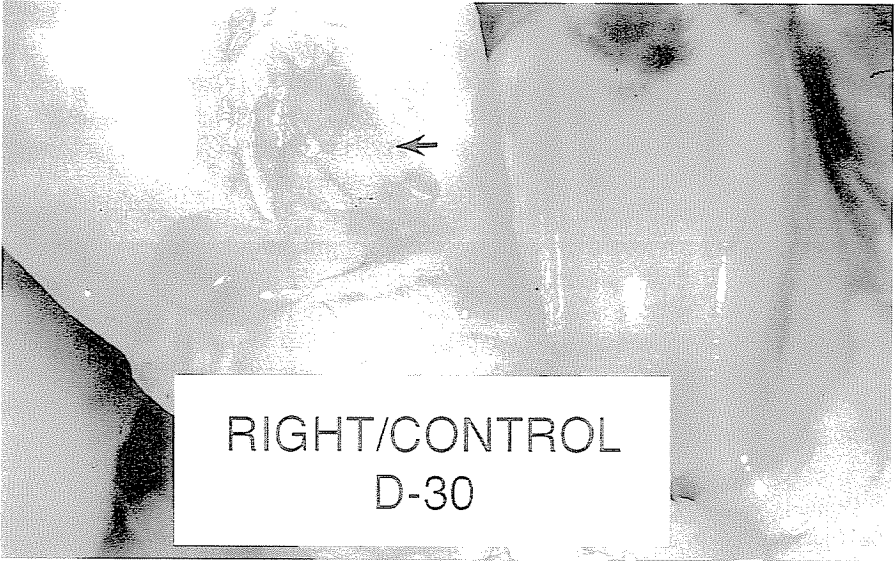

FIGURE 4 A & B. Gross photograph of: A-top) control knee (without spacers) at 6 weeks. Arrows denote the location of the patella; B-bottom) experimental knee (with spacers) at 6 weeks. Arrow denotes the location of the proximal polyethylene spacer

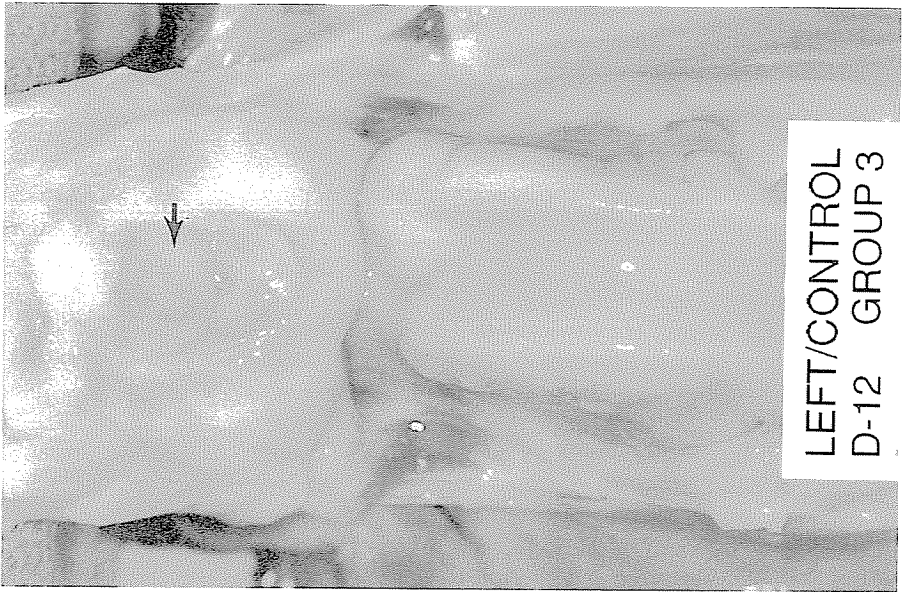
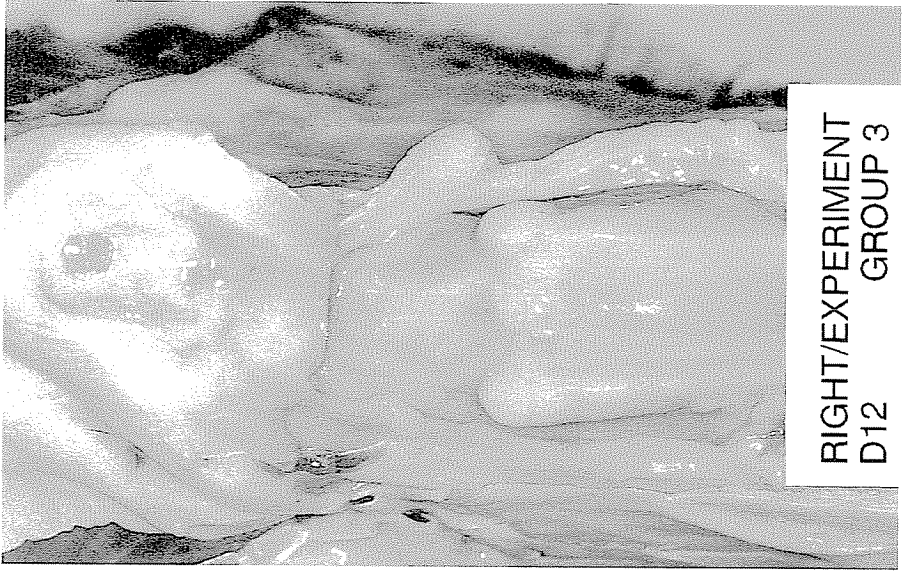

FIGURE 4 C & D. Gross photograph of: C-bottom) control knee (without spacers) at 12 weeks. Arrow denotes the location of the patella; D-top) experimental knee (with spacers) at 12 weeks

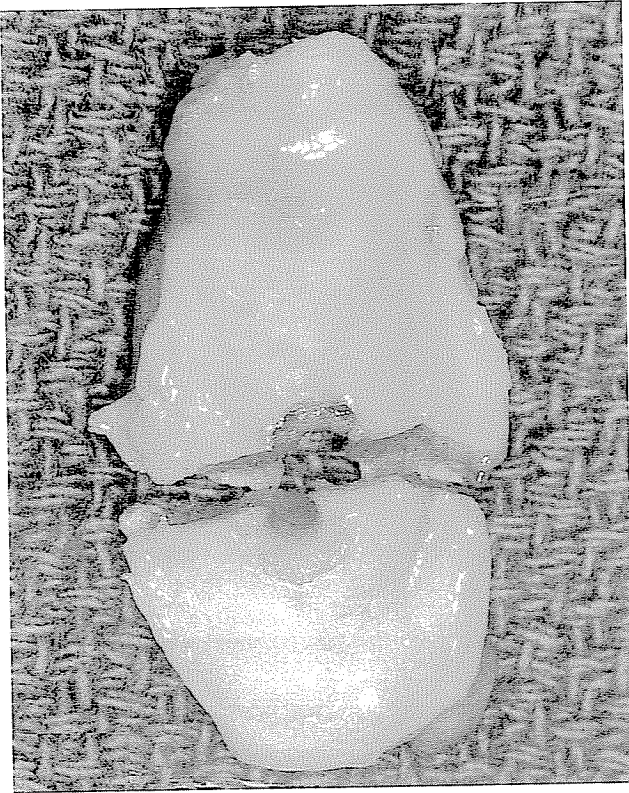


FIGURE 4 E) 12 week patella sectioned transversely through the distal spacer location.

RIGHT/EXPERIMENT D12 GROUP 3

line cartilage. It was not expected to generate normal hyaline cartilage in this environment. The objective was to prove that new tissue would grow upon the subchondral bone in vivo with the joint in motion and to compare the quality of the new tissue to normal hyaline cartilage.

The model is useful as a tool for study of native tissue, modified native tissue, and a wide variety of graft materials inside of an otherwise normal joint while it is in motion. Its particular advantages are the provision of a large surface area for study and the ability to reintroduce normal stresses upon new tissue or graft material at any time point the study requires. In addition, we believe this model will be relatively easy to transfer to many clinical situations.

The approach in the study presented here has other advantages over repair techniques that graft chondrogenic tissue or transplant chondrocyte filled matrices into created defects on a joint surface (Wakitani et al 1989; O'Driscoll et al 1988). This includes the feature that no graft would have to be harvested from the individual and immune reactions would be eliminated. Additionally, the cells growing upon the bleeding bone in our technique may be sufficient to generate neocartilage (Shands

LEFT $\frac{1}{3}$ Central Groove D-30

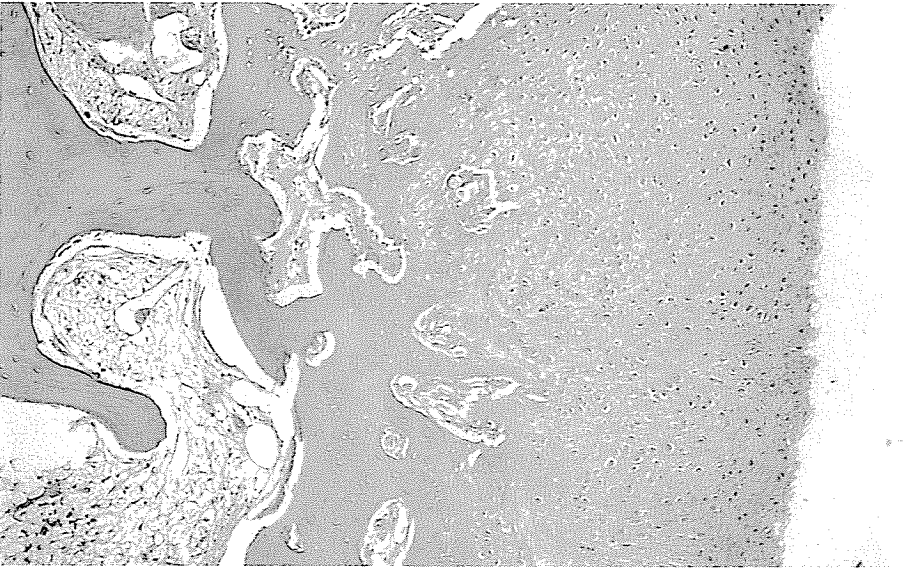



FIGURE 5 A & B. H&E photomicrographs (48X) of: A-top) cartilage from the patellofemoral groove from the experimental knee (with spacers) at 6 weeks; B-bottom) repair tissue on the patella from the experimental knee (with spacers) at 6 weeks

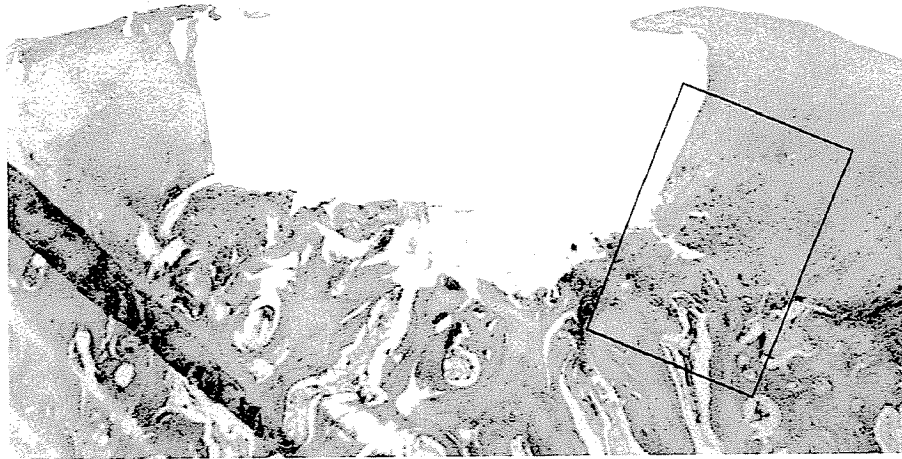
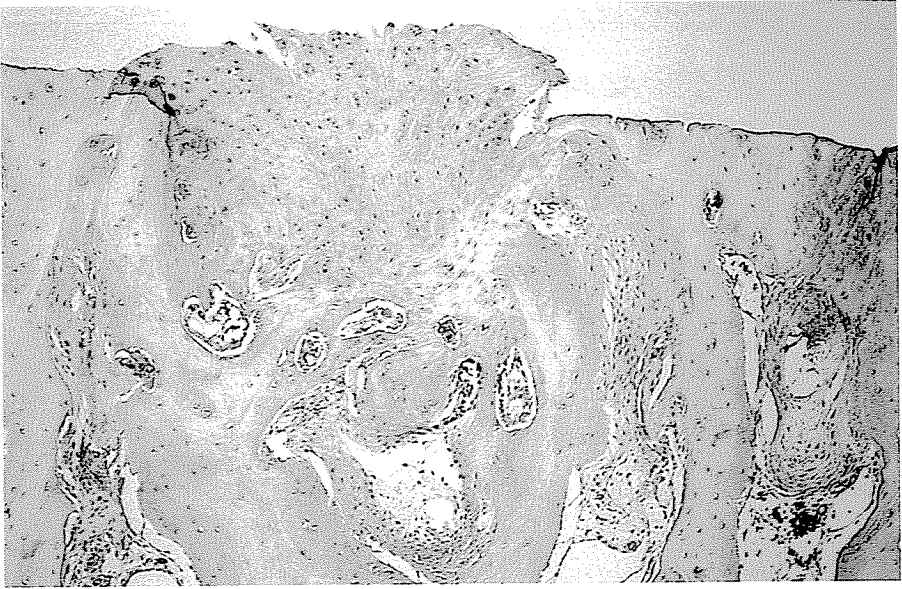


FIGURE 5 C & D. H&E photomicrographs (48X) of: C-top) transverse section of patellae from the control knee (without spacers) at 12 weeks; D-bottom) repair tissue on the patella from the experimental knee (with spacers) at 12 weeks (20X);

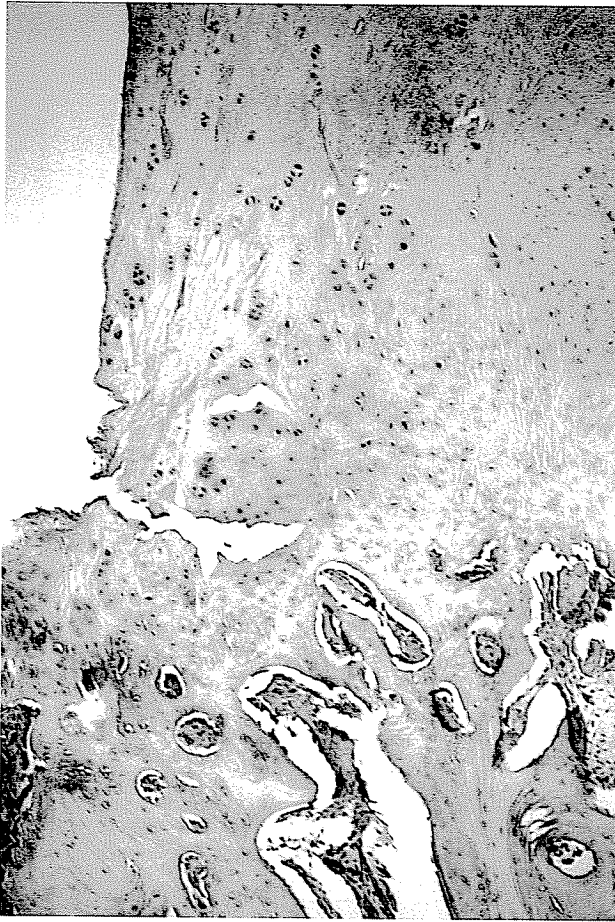


FIGURE 5E. H&E photomicrographs (48X) of: E) closeup view of new tissue shown in (D) (80X).

1931; Shapiro et al 1993; Calandruccio and Gilmer 1962; Campbell 1969; DePalma et al 1966; Trueta and Trias 1961).

As with all biological tissues, cartilage requires a level of stress in order to maintain its homeostasis. It was assumed that maintenance of normal joint motion would permit circulation of synovial fluid and nutrients (as opposed to a model which requires immobilization). This repair tissue will achieve a 3mm stature and is attached to the underlying bone. The repair tissue which grows in our model achieves up to 3mm thickness and is firmly attached to the subchondral bone. This study hypothesized that the repair tissue must be shielded from the large stresses of compression and shear during the early phase of growth and maturation. The new model developed that emphasizes stress-shielding of new growth will allow the repair tissue to achieve a sufficient amount of growth and maturation and attachment to underlying bone to produce a clinically useful surface. The next phase of our study entails removal of the

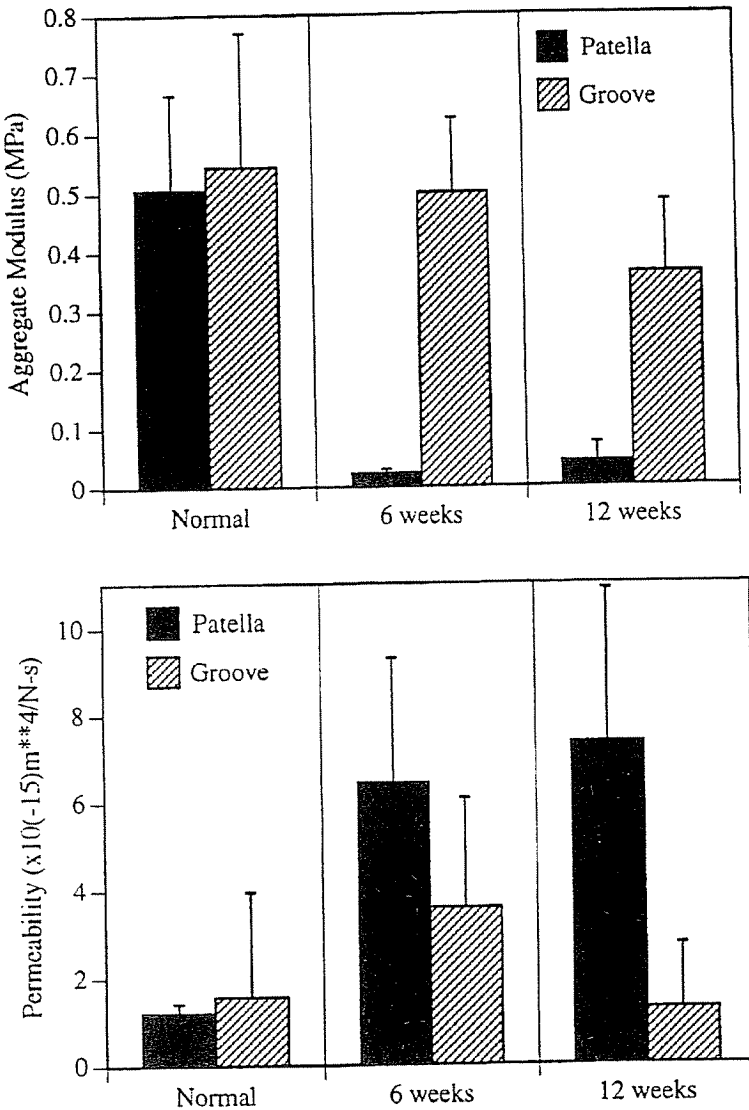


FIGURE 6. Biomechanical properties of the cartilage (mean + standard deviation) from patellae and patellofemoral grooves for normal (external, N=5) and experimental (with spacers, N=6 at each time point) tissue at the two time points studied: A-top) aggregate modulus; B-bottom) apparent permeability.

devices to expose the new tissue to normal joint stress in hope that the new tissue might adapt to this environment by continuing to grow, mature, and transform into hyaline-like cartilage. Further work is needed to investigate the potential of this neocartilage to survive in the normal mechanical environment of the joint after reintroduction of the stresses by removal of the spacers.

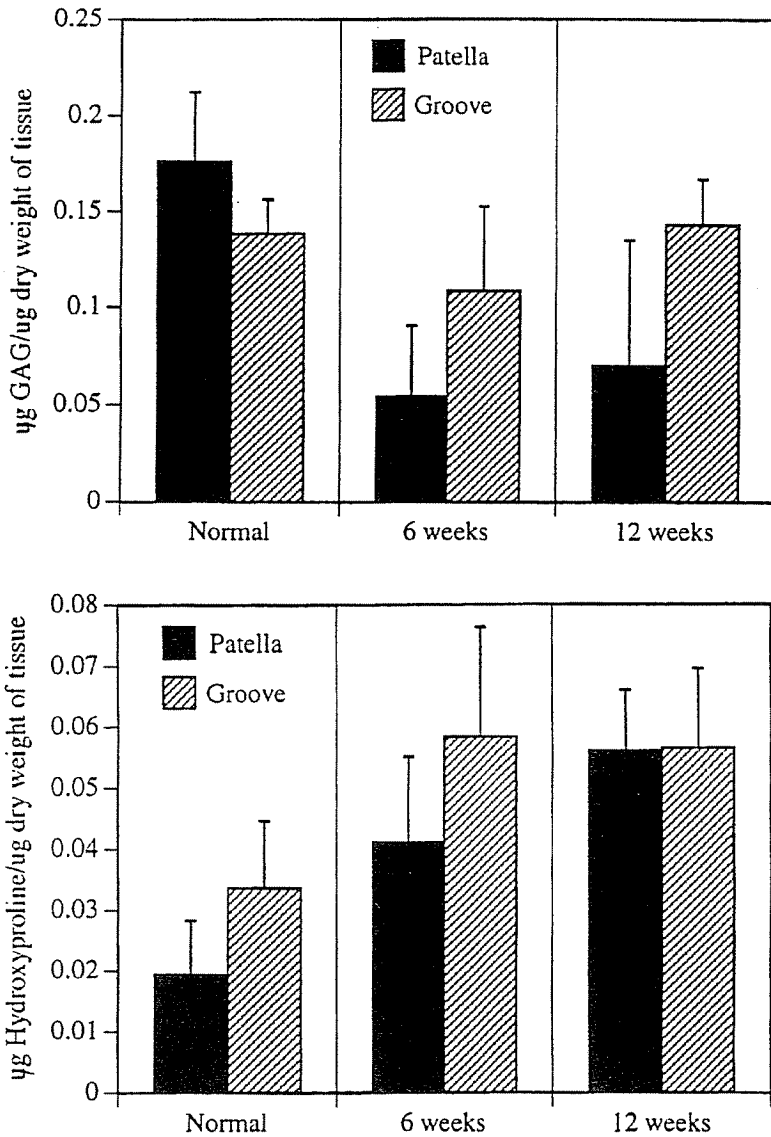


FIGURE 7. Biochemical characteristics of the cartilage from patellae and patellofemoral grooves for normal (external, N=3) and experimental (with spacers, N=6 at each time point) tissue at the two time points studied: A-top) proteoglycan content; B-bottom) collagen content.

ACKNOWLEDGEMENTS

The authors gratefully acknowledge the support of the Veterans Affairs RR&D #AR-799C. Biochemical analyses were performed under the expert direction of Dr. Anthony Ratcliffe of the Orthopaedic Research Laboratory at Columbia University in New York. Dr. Stephen Fiori and Dr. David Peterson provided important assistance during the pilot phase of this work. The authors appreciate the technical assistance of Ms. Kimberly Dailey, Mrs. Nancy Smith, Mr. Chris Brodrick, and Mr. Thomas Scioscia.

Dr. McDowell's contribution to the work included development of the model, leading the surgical team, and the histologic evaluation of the new tissue. Dr. Wayne contributed to the development of the model, developed the method of biomechanical evaluation of the tissue, and participated in all evaluations of the tissue. Dr. Tuten participated in the surgery and joined Drs. McDowell, Wayne, and McGuire in evaluating the results of all tissue testing, compiling the results, developing the conclusions, and considering the implications.

LITERATURE CITED

- Altman RD, Kates J, Chun LE, Dean DD, Eyre D. 1992. Preliminary observations of chondral abrasion in a canine model. *Ann Rheum Dis* 51:1056-1062.
- Athanasίου KA, Rosenwasser MP, Buckwalter JA, Malinin TI, Mow VC. 1991. Interspecies comparisons of in situ intrinsic mechanical properties of distal femoral cartilage. *J Orthop Res* 9:330-340.
- Calandruccio RA, Gilmer WS. 1962. Proliferation, regeneration, and repair of articular cartilage of immature animals. *J Bone Joint Surg Am* 44A:431-455.
- Campbell CJ. 1969. The healing of cartilage defects. *Clin Orthop* 64:45-63.
- Coutts RD, Woo SLY, Amiel D, von Schroeder HP, Kwan MK. 1992. Rib perichondrial autografts in full-thickness articular cartilage defects in rabbits. *Clin Orthop* 275:263.
- DePalma AF, McKeever CD, Subin DK. 1966. Process of repair of articular cartilage demonstrated by histology and autoradiography with tritiated thymidine. *Clin Orthop* 48:229-242.
- Farndale RW, Sayers CA, Barrett AJ. 1982. A direct spectrophotometric microassay for sulfated glycosaminoglycans in cartilage cultures. *Connect Tissue Res* 9:247-248.
- Green WT. 1997. Articular cartilage repair - Behavior of rabbit chondrocytes during tissue culture and subsequent allografting. *Clin Orthop* 124:237-250.
- Guilak F, Meyer BC, Ratcliffe A, Mow VC. 1994. The effects of matrix compression on proteoglycan metabolism in articular cartilage explants. *Osteoarthritis and Cartilage* 2:91-101.
- Gussenbauer C: Über die Heilung Pre Primam Intentionem. *Archives F. Klin. Chirurgica*. 1871. 12:791.
- Hale HE, Rudert MJ, Mohler CG, Brown TD. 1993. Indentation assessment of biphasic mechanical property deficits in size-dependent osteochondral defect repair. *J Biomech* 26:1319-1325.
- Hendrickson DA, Nixon AJ, Grande DA, Todhunter RJ, Minor RM, Erb H, et al. 1994. Chondrocyte-fibrin matrix transplants for resurfacing extensive articular cartilage defects. *J Orthop Res* 12:485-597.

- Hunter W. 1743. On the structure and diseases of articulating cartilage. *Philos Trans R Soc Lond* 42:514.
- Ito LK. 1924. The nutrition of articular cartilage and its method of repair. *Br J Surg* 12:31-42.
- Johnson L.L. 1986. Arthroscopic abrasion arthroplasty historical and pathologic perspective - Present status. *Arthroscopy* 2:54-69.
- Jurvelin JS, Rasanen T, Kolmonen P, Lyyra T. 1995. Comparison of optical, needle probe and ultrasonic thickness techniques for the measurement of articular cartilage thickness. *J Biomech*, 28:231-235.
- Kim HKW, Moran ME, Salter RB. 1991. The potential for regeneration of articular cartilage in defects created by chondral shaving and subchondral abrasion. An experimental investigation in rabbits. *J Bone Joint Surg Am* 73A:1301-1315.
- Kwak SD, Newton PM, Setton LA, Grelsamer RP. 1993. Cartilage thickness and contact area determination in the canine knee joint. *Trans Orthop Res Soc* 18:351.
- Mak AF, Lai WM, Mow VC. 1987. Biphasic indentation of articular cartilage - I. Theoretical solution. *J Biomech* 20:703-714.
- Mankin HJ. 1962. Localization of tritiated thymidine in articular cartilage of rabbits - Repair in immature cartilage. *J Bone Joint Surg Am* 44A:688-698.
- Mankin HJ. 1982. Current concepts review - The response of articular cartilage to mechanical injury. *J Bone Joint Surg Am* 64A:460-466.
- Mitchell N, Shepard N. 1976. The resurfacing of adult rabbit articular cartilage by multiple perforations through subchondral bone. *J Bone Joint Surg Am* 58A:230-233.
- Mitchell N, Shepard N. 1992. Effect of patellar shaving in the rabbit. *J Orthop Res* 5:388-392.
- Moran M, Kim H, Salter R. 1992. Biological resurfacing of full-thickness defects in patellar articular cartilage of the rabbit. *J Bone Joint Surg Br* 74B:659-667.
- Mow VC, Gibbs, MC, Lai WM, Zhu WB, Athanasiou KA. 1989. Biphasic indentation of articular cartilage - II. A numerical algorithm and an experimental study. *J Biomech* 22:853-862.
- Mow VC, Kuei SC, Lai WM, Armstrong CG. 1980. Biphasic creep and stress relaxation of articular cartilage in compression - Theory and experiments. *J Biomech Eng* 102:73-84.
- Mow VC, Ratcliffe A, Rosenwasser MP, Buckwalter JA. 1991. Experimental studies on repair of large osteochondral defects at a high weight bearing area of the knee joint: A tissue engineering study. *J Biomech Eng* 113:198-207.
- O'Driscoll SW, Keeley FW, Salter RB. 1986. The chondrogenic potential of free autogenous periosteal grafts for biological resurfacing of major full-thickness defects in joint surfaces under the influence of continuous passive motion - An experimental investigation in the rabbit. *J Bone Joint Surg Am* 68A:1017-1035.
- O'Driscoll SW, Keeley FW, Salter RB. 1988. Durability of regenerated articular cartilage produced by free autogenous periosteal grafts in major full-thickness defects in joint surfaces under the influence of continuous passive motion. *J Bone Joint Surg Am* 70A:595-606.
- O'Driscoll SW, Salter RB. 1986. The repair of major osteochondral defects in joint surfaces by neochondrogenesis with autogenous osteoperiosteal grafts stimulated

- by continuous passive motion - An experimental investigation in the rabbit. *Clin Orthop* 208:131-140.
- Pineda S, Pollack A, Stevenson S, Goldberg V, Caplan A. 1992. A semiquantitative scale for histologic grading of articular cartilage repair. *Acta Anatomica* 143:335-340.
- Richmond JC, Gambardella PG, Schelling S, McGinty JB, Schwartz ER. 1985. A canine model of osteoarthritis with histologic study of repair tissue following abrasion arthroplasty. *Trans Orthop Res Soc* 10:61.
- Rodrigo JJ, Steadman JR, Silliman JF, Fulstone A. 1991. Improvement of chondral defect healing after chondroplasty by the use of continuous passive motion. *Trans Orthop Res Soc* 16:277.
- Shands AR. 1931. The regeneration of hyaline cartilage in joints - An experimental study. *Arch Surg* 22:137-178.
- Shapiro F, Koide S, Glimcher MJ. 1993. Cell origin and differentiation in the repair of full-thickness defects of articular cartilage. *J Bone Joint Surg Am* 75A:532-553.
- Stegemann H, Stadler K. 1967. Determination of hydroxyproline. *Clin Chim Acta* 19:267-27.
- Trueta J, Trias A. 1961. The vascular contribution to osteogenesis - IV. The effect of pressure upon the epiphyseal cartilage of the rabbit. *J Bone Joint Surg Br* 43B:800.
- von Schroeder HP, Billings E, Kwan M, Amiel D, Wayne J, Harwood F, et al. 1990. The use of demineralized bone and rib perichondrium composite grafts for the repair of full thickness articular defects. *Trans Orthop Res Soc* 15(2):346.
- von Schroeder HP, Kwan M, Amiel D, Coutts RD. 1991. The use of polylactic acid matrix and periosteal grafts for the reconstruction of rabbit knee articular defects. *J Biomed Mater Res* 25:329-339.
- Wakitani S, Goto T, Pineda S, Young R, Mansour J, Caplan A, et al. 1994. Mesenchymal cell-based repair of large, full-thickness defects of articular cartilage. *J Bone Joint Surg Am* 76:579-592.
- Wakitani S, Kimura T, Hirooka A, Ochi T, Yoneda M, Yasui N, et al. 1989. Repair of rabbit articular surfaces with allograft chondrocytes embedded in collagen gel. *J Bone Joint Surg Br* 71B:74-80.
- Woo SLY, Kwan MK, Lee TQ, Field FP, Kleiner JB, Coutts RD. 1987. Perichondrial autograft for articular cartilage. Shear modulus of neocartilage studied in rabbits. *Acta Orthop Scand* 58:510-515.
-