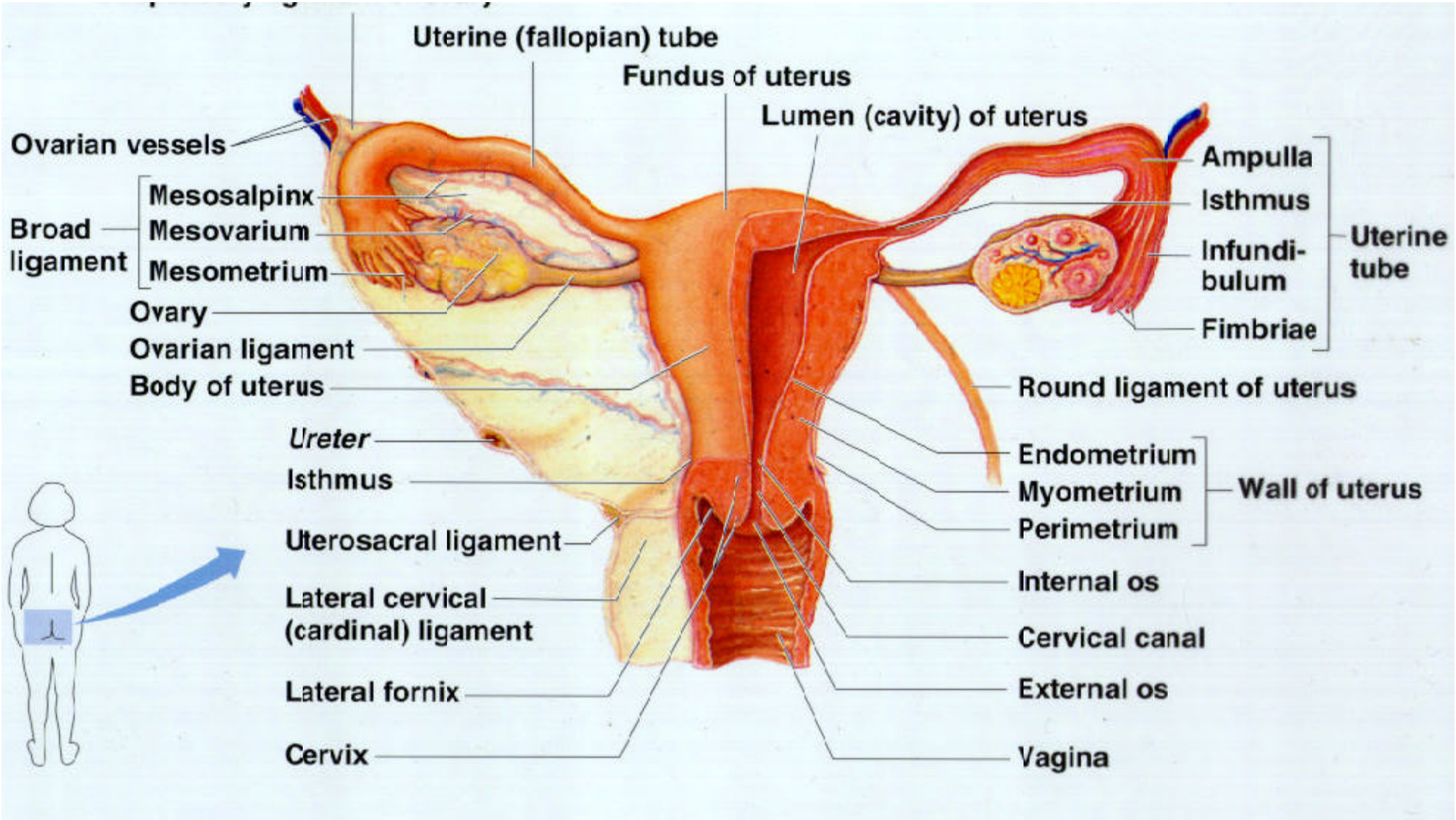
Uterine (fallopian) tube
Fundus of uterus
Lumen (cavity) of uterus
Ovarian vessels
Broad ligament
Mesosalpinx
Mesovarium
Mesometrium
Ovary
Ovarian ligament
Body of uterus
Ureter
Isthmus
Uterosacral ligament
Lateral cervical (cardinal) ligament
Lateral fornix
Cervix
Ampulla
Isthmus
Infundi-bulum
Fimbriae
Uterine tube
Round ligament of uterus
Endometrium
Myometrium
Perimetrium
Wall of uterus
Internal os
Cervical canal
External os
Vagina