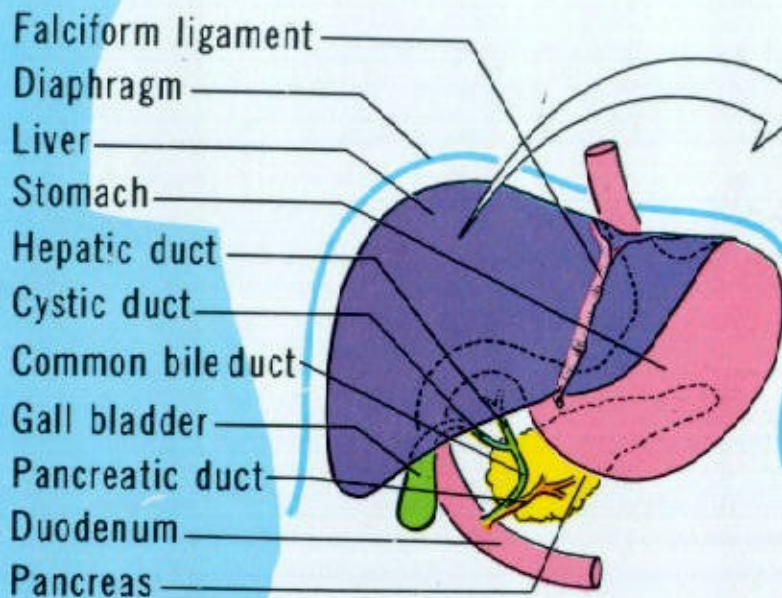
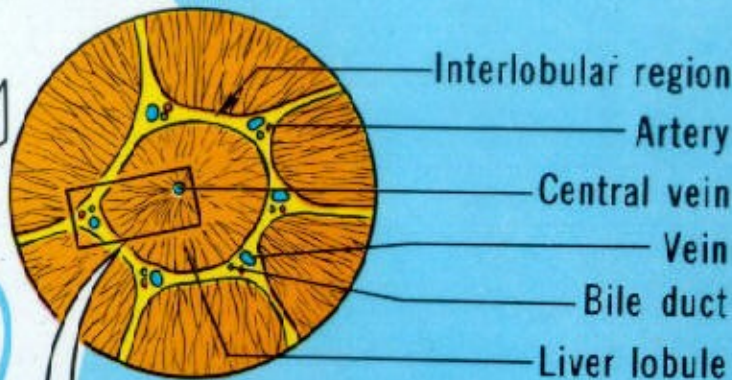


# LIVER

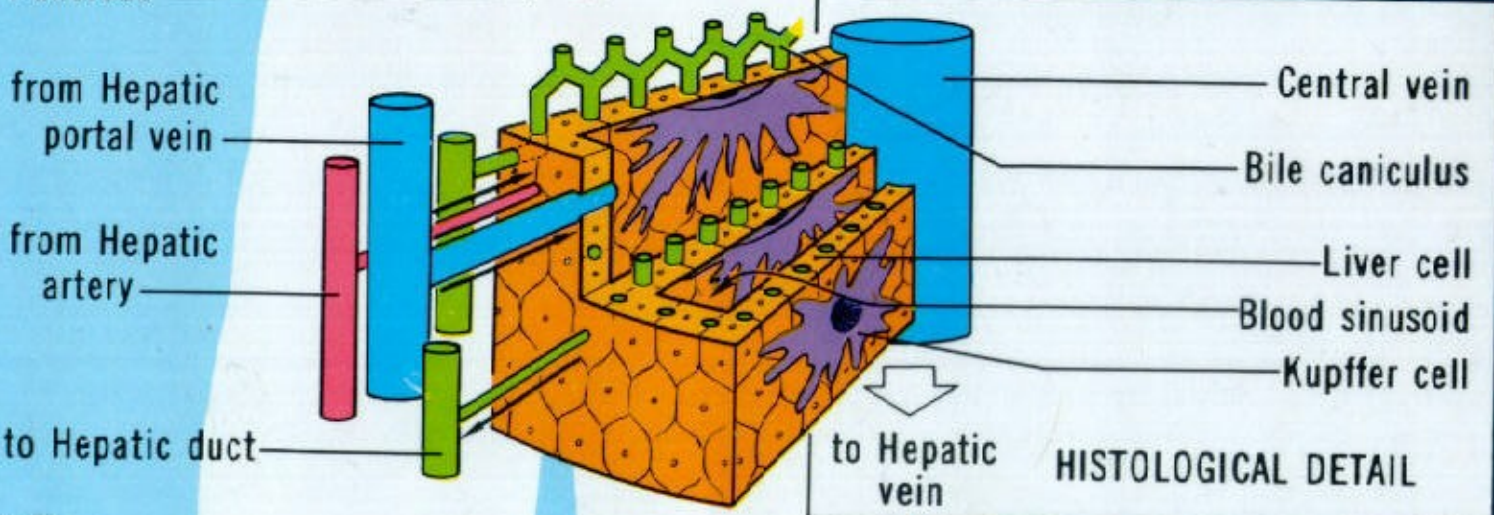


- Falciform ligament
- Diaphragm
- Liver
- Stomach
- Hepatic duct
- Cystic duct
- Common bile duct
- Gall bladder
- Pancreatic duct
- Duodenum
- Pancreas



- Interlobular region
- Artery
- Central vein
- Vein
- Bile duct
- Liver lobule

## LOBULE DETAIL



- from Hepatic portal vein
- from Hepatic artery
- to Hepatic duct

- Central vein
- Bile caniculus
- Liver cell
- Blood sinusoid
- Kupffer cell

to Hepatic vein

## HISTOLOGICAL DETAIL